

Forum Minireview

New Frontiers in Gut Nutrient Sensor Research: Prophylactic Effect of Glutamine Against *Helicobacter pylori*-Induced Gastric Diseases in Mongolian Gerbils

Kikuko Amagase^{1,†}, Eiji Nakamura^{1,2,†,*}, Takuya Endo¹, Shusaku Hayashi¹, Mai Hasumura², Hisayuki Uneyama², Kunio Torii², and Koji Takeuchi¹

¹Division of Pathological Sciences, Department of Pharmacology and Experimental Therapeutics, Kyoto Pharmaceutical University, Misasagi, Yamashina, Kyoto 607-8414, Japan

²Physiology & Nutrition Group, Institute of Life Sciences, Ajinomoto Co., Inc., 1-1 Suzuki-cho, Kawasaki-ku, Kawasaki 210-8681, Japan

Received June 19, 2009; Accepted October 15, 2009

Abstract. Ammonia is one of the important toxins produced by *Helicobacter pylori* (*H. pylori*), the major cause of peptic ulcer diseases. We examined whether glutamine or marzulene (a gastro-protective drug containing 1% sodium azulene and 99% glutamine) protects the gastric mucosa against *H. pylori* in vivo and investigated the mechanism underlying glutamine-induced mucosal protection against ammonia in gastric epithelial cells in vitro. Mongolian gerbils were fed for 3 months with a diet containing glutamine (2% – 20%) or marzulene (20%) starting from 2 weeks or 2 years after *H. pylori* infection. Then, gastric mucosal changes were evaluated both macro- and microscopically. Cultured gastric epithelial cells were incubated in the presence of ammonia, with or without glutamine; and cell viability, ammonia accumulation, and chemokine production were determined. Gerbils exhibited edema, congestion, and erosion after 3-month infection; and after 2-year infection, they showed cancer-like changes in the gastric mucosa. Glutamine and marzulene significantly suppressed these pathological changes caused in the gastric mucosa by *H. pylori* infection. Ammonia was accumulated in the cells, resulting in an increase in chemokine production and a decrease in cell viability. These pathological responses were prevented by glutamine. In addition, glutamine decreased chemokine production and cell death through inhibition of cellular accumulation of ammonia, resulting in the prevention of *H. pylori*-induced gastric diseases in vivo. These results suggest that glutamine/marzulene would be useful for prophylactic treatment of *H. pylori*-induced gastric diseases in patients.

Keywords: glutamine, gastric mucosa, *Helicobacter pylori*, protection, cell death, gastrointestinal tract

1. Introduction

Since the discovery of *Helicobacter pylori* (*H. pylori*) as the pathogenic bacteria in digestive diseases such as gastritis, gastroduodenal ulcer, and gastric cancer, many investigators have reported various deleterious factors produced by *H. pylori* (1 – 3). Among them, vacuolating

cytotoxin (VacA), gene products of the Cag pathogenicity island (PAI), and urease-derived ammonia are now generally accepted pathogenic factors (4). Interestingly, in addition to the original cytotoxic properties, recent reports proposed the unexpected new roles of VacA and Cag PAI gene products in the pathogenesis of *H. pylori*-induced gastric diseases through acting on tyrosine phosphatases and their receptors (5 – 7). However, target gene-deletion analysis revealed that not only VacA-deleted *H. pylori* causes severe gastritis, but CagE- or Cag PAI-deleted isogenic strains also induce gastritis in the gerbil model as well (8). Moreover,

[†]These authors contributed equally to this manuscript.

*Corresponding author. eiji_nakamura@ajinomoto.com

Published online in J-STAGE

doi: 10.1254/jphs.09R11FM

H. felis, a related gastric *Helicobacter* that lacks VacA or Cag PAI but has potent urease activity, induces severe gastritis and gastric cancer in several animal models (9–11). These results suggest the pathogenic importance of urease-derived ammonia, rather than that of VacA or gene product of Cag PAI, in the formation of gastritis induced by *H. pylori*. Indeed, a number of studies showed that ammonia, at a concentration detectable in the gastric juice of *H. pylori*-infected patients, inhibits gastric epithelial proliferation (12), retards restitution (13), and induces mucosal cell death (14–17) and by so, doing impairs the gastric mucosal barrier function.

We previously reported that glutamine added exogenously protects gastric epithelial cells against ammonia-induced cell death (16). However, it remains still unknown whether or not glutamine is effective against *H. pylori*-induced diseases in vivo. In the present study, we thus examined the effect of chronic treatment with high glutamine- or marzulene-containing diet on *H. pylori*-induced pathological changes in the stomach and investigated the mechanisms underlying the protective action of glutamine against ammonia using cultured gastric epithelial cells in vitro.

2. Materials and Methods

2.1. Animals

Male Mongolian gerbils (6-week-old, 40–50 g), purchased from Seac Yoshitomi (Fukuoka), were maintained in an isolated clean room with regulated temperature (20°C–22°C) and humidity (approximately 55%) with a 12/12-h light/dark cycle. The gerbils were fasted for 24 h before *H. pylori* inoculation, and drinking water was also withheld after the inoculation. Then, both food and water were freely available to the animals from 4 h after the inoculation. The animal maintenance and experimental procedures described here were approved by the Experimental Animal Research Committee of Kyoto Pharmaceutical University.

2.2. *H. pylori* infection to Mongolian gerbils

A cagA- and vacA-positive strain of *H. pylori* (TN2GF4), derived from a gastric ulcer patient, was kindly provided by Dr. Watanabe (Takeda Chemical Industries, Ltd., Osaka) (18). The bacteria were incubated in brain-heart infusion broth (Difco, Detroit, MI, USA) containing 10% fetal bovine serum at 37°C overnight under a microaerophilic atmosphere and allowed to grow to a density of 2×10^8 colony-forming units (CFU) / ml. *H. pylori* (2×10^8 CFU, 1.0 ml) was orally inoculated to each animal. Normal animals received 1.0 ml of the medium alone. In a short-term gastritis study, paste foods containing 2%, 10%, and 20% (w/w) glutamine

or marzulene (a gastroprotective drug containing 1% sodium azulene and 99% glutamine, prescribed in East Asian countries such as Japan, Korea, and China) were given to the gerbils twice daily (10 g/animal per day) for 3 months, starting 2 weeks after *H. pylori* inoculation. In a long-term gastric cancer study, the diets were given for 3 months starting from 2 years after infection. In both studies, at the end of experiments the pathological changes in the gastric mucosa were evaluated macroscopically. Paste food was made of 1.4 kg CE-2 (CLEA Japan, Tokyo), 30 g gelatin (Morinaga & Co., Ltd., Tokyo), and 1.4 l distilled water. To avoid degradation of the drugs, glutamine or marzulene was mixed with the paste food every time immediately before feeding it to the animals. Glutamine and marzulene were supplied from Kotobuki Pharmaceutical Co., Ltd. (Nagano)

2.3. Determination of viable *H. pylori* in stomach

The number of viable *H. pylori* in the gerbil stomach was assayed as reported previously (19). After the gerbils were fasted for 24 h, they were sacrificed, and their stomachs were excised. Halves of the stomachs were homogenized in 10 ml of PBS with a Polytron (Kinematica, Steinhofhalde, Switzerland). The diluted homogenates were applied onto *Helicobacter* agar plates (Nissui Pharmaceutical Co., Ltd., Tokyo). The plates were incubated at 37°C under a microaerophilic atmosphere for 7 days. The number of colonies was counted, and viable *H. pylori* was expressed as CFU per stomach.

2.4. Evaluation of *H. pylori*-induced gastric damages

Gastric pathology was blindly evaluated. Normal and *H. pylori*-infected animals were killed, and their stomachs were excised. The stomachs were incised along the greater curvature and spread out with pins on a silicon-coated 6-cm dish and then the wet weight of the stomach, as an indicator of inflammation due to edema, was measured. Mucosal changes such as bleeding (spot/erosion), congestion, edema, ulcer, and hyperplastic polyp (mm²) were examined under a dissecting microscope (magnification, 10×). Thereafter, gastric specimens were cut off from the fundus near the antrum and fixed in 4% paraformaldehyde in PBS. Frozen sections (12 μm in thickness) were prepared, and neutrophil-specific myeloperoxidase activity-dependent staining and hematoxylin staining were carried out. Gastric mucosal thickness was evaluated using a microscopic scale.

2.5. Cell culture

Rat gastric epithelial cell lines, RGM1 cells established by Dr. Matsui, Institute of Physical and Chemical Science (RIKEN) Cell Bank and Institute of Clinical Medicine, University of Tsukuba, Tsukuba, Japan

(20), were used as non-transformed gastric surface epithelial cells. RGM1 cells were cultured in DMEM/F12 (1:1) supplemented with heat-inactivated 10% FBS (Gibco/BRL, Gaithersburg, MA, USA), 100 units/ml penicillin, 100 units/ml streptomycin, and 0.25 $\mu\text{g}/\text{ml}$ amphotericin B. Then, the cells were starved for 24 h in culture medium without FBS (DMEM/F12 containing 15 mM HEPES at pH 7.4) at 37°C under 5% CO₂ in air. Starved RGM1 cells were incubated with the indicated reagents in standard (STD) buffer containing 147 mM Na⁺, 5.0 mM K⁺, 131 mM Cl⁻, 1.3 mM Mg²⁺, 1.3 mM SO₄²⁻, 2 mM Ca²⁺, 25 mM HCO₃⁻, 15 mM HEPES, and 20 mM D-glucose at pH 7.4. NH₄Cl (Sigma Chemical Company, St. Louis, MO, USA) was used as the source of ammonia (NH₃). To investigate the mechanisms by which glutamine protects RGM1 cells against ammonia, the cells were incubated in the absence or presence of 30 mM NH₄Cl with or without glutamine for the indicated hours and then used for determination of intracellular ammonia accumulation (6 h), chemokine production [cytokine-induced neutrophil chemoattractant (CINC/GRO)] release (12 h) and cell viability (24 h).

To confirm that the response of RGM1 cells is generalized to human gastric epithelial cells, we used a human gastric epithelial-like cell line derived from a gastric adenocarcinoma patient, MKN74 cells (obtained from the Riken Cell Bank, Tsukuba, Japan), for determination of chemokine (interleukin-8; IL-8) production (24 h) and cell viability (96 h).

2.6. Measurement of ammonia accumulation

Since vacuolation is an indicator of the intracellular amount of weak base, we evaluated the intracellular concentration of ammonia by quantifying vacuolation. To quantify vacuolation in RGM1 cells, the uptake of neutral red into vacuoles was determined as described by Cover et al. (16, 21, 22), with slight modification. Vacuolation was calculated as % increase compared with vehicle alone-treated cells.

2.7. Measurement of chemokine release

Chemokine releases from the cells into the culture medium were measured by commercially available ELISA kits (CINC/GRO for RGM1 cells and IL-8 for MKN74; R&D Systems, Inc., Minneapolis, MN, USA).

2.8. Measurement of cell viability

The cell viability was evaluated by a colorimetric assay using crystal violet (23), a cytochemical stain that binds to chromatin. Viability was calculated as % of vehicle alone-treated cells.

2.9. Statistical analysis

Data of in vivo study are presented as the mean \pm S.E.M. from 6 to 16 gerbils per group, while those of in vitro study are the representative results from 3 different experiments and presented as the means \pm S.E.M. from 4 wells. Statistical differences in the dose-response studies were evaluated by Dunnett's multiple comparison test. Student's *t*-test or the Mann-Whitney U test was used for the comparison between two groups. A value of $P < 0.05$ was regarded as significant.

3. Results

3.1. Effect of glutamine and marzulene on gastric damages induced by short-term *H. pylori* infection in gerbils

In non-infected gerbils, all the groups including control diet, glutamine at 20%, and marzulene at 20% showed no abnormal pathological changes in the gastric mucosa (Fig. 1A). In addition, the stomach wet weight (Fig. 1B) and the gastric mucosal thickness (data not shown) were very much similar among these groups. When the gerbils were infected with *H. pylori* for 3 months, the control diet group showed dramatic pathological changes characterized by severe edema, congestive surface epithelium, and bleeding, vastly in the corpus and some in the antral area. In addition, the stomach wet weight (Fig. 1B) and the gastric mucosal thickness (data not shown) were significantly increased after *H. pylori* infection for 3 months. Histological analyses revealed extensive exfoliation of the surface epithelial cells and severe infiltration of inflammatory cells (mainly neutrophils) in the gastric mucosa. In contrast, the glutamine-treated groups exhibited a dose-dependent improvement of the pathological changes in all these parameters. Even at 2% glutamine, the pathological changes were significantly less compared with those in the control group. At 20% glutamine, the surface epithelial structure was partially recovered and the level of inflammatory cell infiltration was reduced. Likewise, marzulene at 20% also significantly reduced the pathological changes of the stomach caused by *H. pylori*. Interestingly, treatment with 20% glutamine caused a slight reduction in the viable *H. pylori* number in the stomach compared with the control, although the difference did not reach the level of bacteriological significance (Fig. 2).

3.2. Effect of glutamine and marzulene on gastric carcinoma-like changes induced by long-term *H. pylori* infection in gerbils

Two-years infection with *H. pylori* caused carcinoma-like changes in the gastric mucosa, characterized by hyperplastic polyps (Figs. 3A and 4) and metaplasia

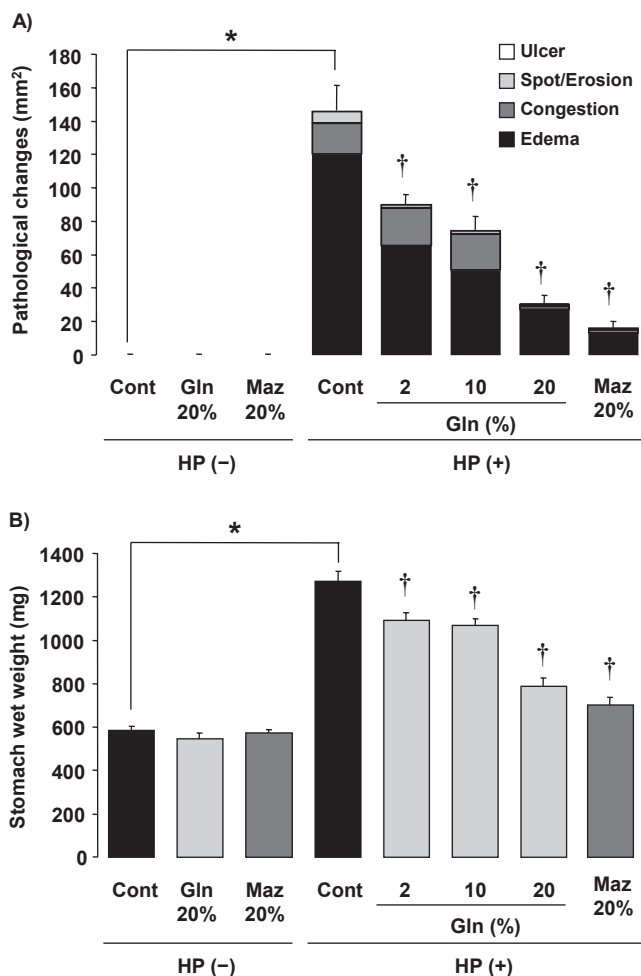


Fig. 1. Effects of glutamine and marzulene on gastric damages (A) and gastric wet weight changes (B) induced by short-term *H. pylori* infection in gerbils. Two weeks after *H. pylori* inoculation, non-infected [HP(-)] and *H. pylori*-infected [HP(+)] gerbils were given paste foods containing 0 (Control), 2%, 10%, and 20% glutamine (Gln) or 20% marzulene (Maz), twice daily (10 g/animal/day) for 3 months; and the gastric mucosal pathologic changes were macroscopically evaluated. Data are presented as the mean \pm S.E.M. from 7–16 gerbils. Significant difference at $P < 0.05$: *from HP(-) Control, †from HP(+) Control. (Adapted from Ref. 35 with permission.)

(data not shown), in addition to the changes caused by short-term *H. pylori* infection. Histologically, gastric atrophy, that is, the reduction in the number of gastric acid-secreting parietal cells and pepsinogen-secreting chief cells and intestinal metaplasia were also observed in the long-term-infected gastric mucosa. Three-month treatment with 20% glutamine or 20% marzulene diet alone caused no abnormal changes in the stomach in the absence of *H. pylori* infection. Surprisingly, feeding with 20% glutamine or 20% marzulene diet significantly reduced the total area of mucosa with such pathological changes caused by long-term *H. pylori* infection, especially, hyperplastic polyps. Furthermore, when

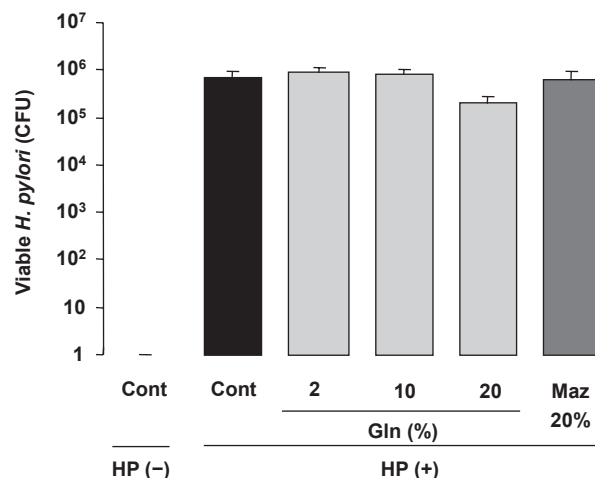


Fig. 2. Effects of glutamine and marzulene on *H. pylori* number in the stomach of gerbils in short-term *H. pylori* infection experiment. Two weeks after *H. pylori* inoculation, non-infected [HP(-)] and *H. pylori*-infected [HP(+)] gerbils were given paste foods containing 0 (Control), 2%, 10%, and 20% glutamine (Gln) or 20% marzulene (Maz), twice daily (10 g/animal/day) for 3 months; and the viable *H. pylori* was evaluated using the culture method and indicated as colony forming (CFU). Data are presented as the mean \pm S.E.M. from 6–8 gerbils.

the degree of each pathological change was compared among the groups, a significant difference was observed in cases of hyperplastic polyps and edema (not shown). In addition, these agents also ameliorated the increase of the stomach wet weight caused by *H. pylori* infection (Fig. 3B).

3.3. Effect of glutamine on ammonia accumulation in RGM1 cells

Incubation with 30 mM NH_4Cl for 6 h caused significant increase in the accumulation of ammonia in the cells compared with the control. When RGM1 cells were incubated with 30 mM NH_4Cl in the presence of glutamine (0.2–20 mM), the amount of ammonia in the cells was decreased in a concentration-dependent manner for glutamine (Fig. 5A). This agent even at 0.2 mM significantly reduced the accumulation of ammonia in the cells and at 20 mM almost completely abolished this response.

3.4. Effect of glutamine on NH_4Cl -induced chemokine release by RGM1 cells

The release of CINC/GRO was significantly increased when RGM1 cells were incubated with 30 mM NH_4Cl for 12 h (Fig. 5B). Co-incubation of glutamine concentration-dependently suppressed the increase of CINC/GRO release from RGM1 cells caused by NH_4Cl , and this effect was significant at 2 mM or greater.

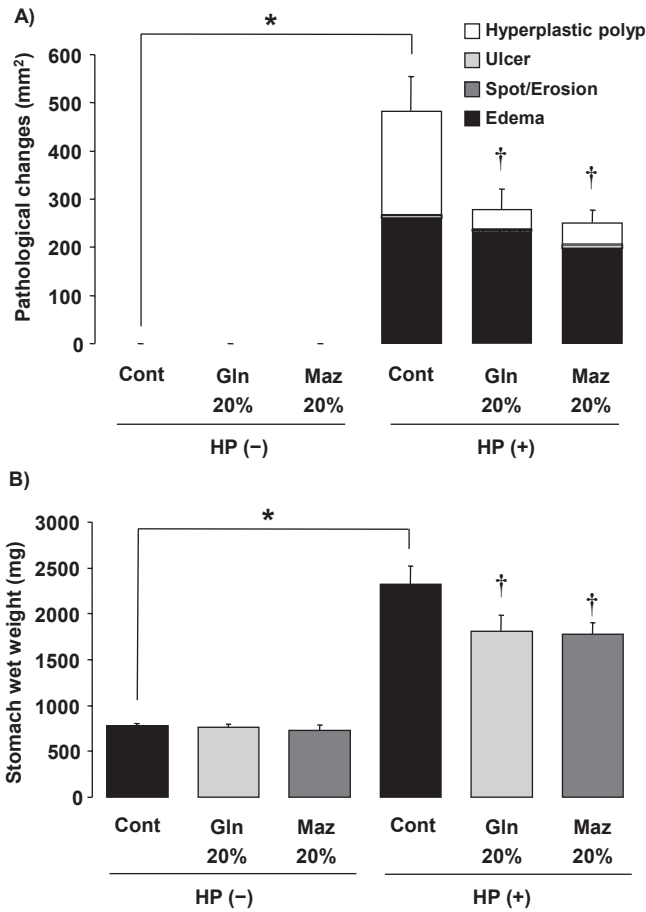


Fig. 3. Effects of glutamine and marzulene on gastric pathological changes (A) and gastric wet weight changes (B) induced by long-term *H. pylori* infection in gerbils. Two years after *H. pylori* inoculation, non-infected [HP(-)] and *H. pylori*-infected [HP(+)] gerbils were given paste foods containing 0 (Control), 20% glutamine (Gln), or 20% marzulene (Maz), twice daily (10 g/animal/day) for 3 months; and the gastric mucosal pathologic changes were macroscopically evaluated. Data indicate total area (mm²) of the mucosa with pathological changes and are presented as the mean ± S.E.M. from 6–9 gerbils. Significant difference at *P* < 0.05: *from HP(-) Control, †from HP(+) Control. (Adapted from Ref. 35 with permission.)

3.5. Effect of glutamine on NH₄Cl-induced gastric epithelial cell death in RGM1 cells

As shown in Fig. 5C, the incubation of RGM1 cells with 30 mM NH₄Cl significantly increased the intracellular accumulation of ammonia at 6 h and the release of CINC/GRO at 12 h and decreased cell viability 24 h later. Glutamine (0.2 – 20 mM) significantly mitigated the reduction of cell viability in a concentration-dependent manner and at 20 mM, almost completely restored the reduced cell viability to the level observed in the control.

3.6. Effect of glutamine and NH₄Cl on chemokine release and cell viability of MKN74 cells

Similar to RGM1 cells, when MKN74 cells were incubated with 30 mM NH₄Cl, IL-8, one of the chemokines, was released in the culture medium in a time-dependent manner. The levels of IL-8 observed 24 h after the incubation were significantly greater compared with those in the control. The co-incubation with glutamine even at 0.2 mM partially but significantly and at more than 2 mM totally suppressed the increase of IL-8 release caused by 30 mM NH₄Cl (Fig. 6A). Incubation of MKN74 cells with 30 mM NH₄Cl also caused a significant reduction of the cell viability 96 h later. Glutamine (0.2 – 20 mM) significantly prevented the reduction of cell viability in a concentration-dependent manner, the degree of prevention at 20 mM being almost 100% (Fig. 6B).

4. Discussion

Non-steroidal anti-inflammatory drugs (NSAIDs) and stress are known to be the major pathogenic factors in the development of gastric lesions in rats and humans (24). In addition, NSAIDs also delay the healing of acetic acid-induced gastric ulcer in rats (25). Since

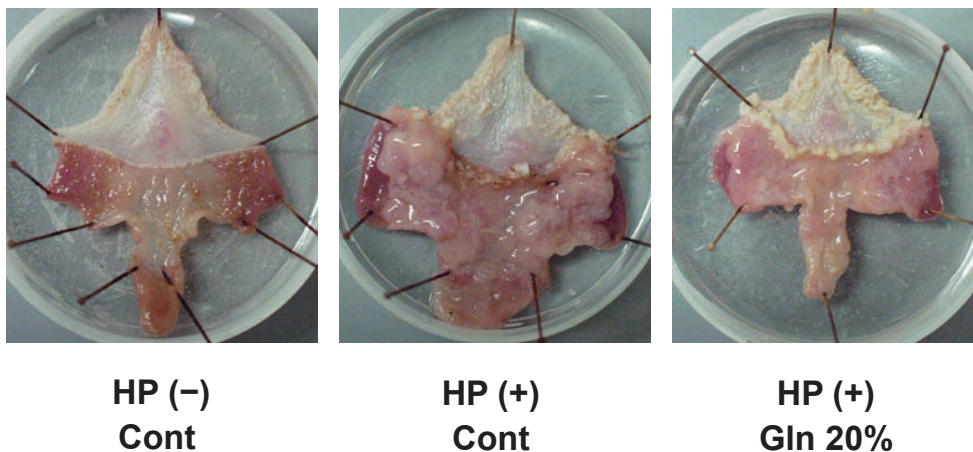


Fig. 4. Macroscopical observation of gastric mucosa treated with glutamine in long-term *H. pylori* infection in gerbils. Two years after *H. pylori* inoculation, non-infected [HP(-)] and *H. pylori*-infected [HP(+)] gerbils were given paste foods containing 0 (Control) or 20% glutamine (Gln), twice daily (10 g/animal/day) for 3 months. Note that hyperplastic polyps and severe edema with thickened mucosa were observed in HP(+) stomach, but glutamine treatment improved such abnormalities of the stomach. (Adapted from Ref. 35 with permission.)

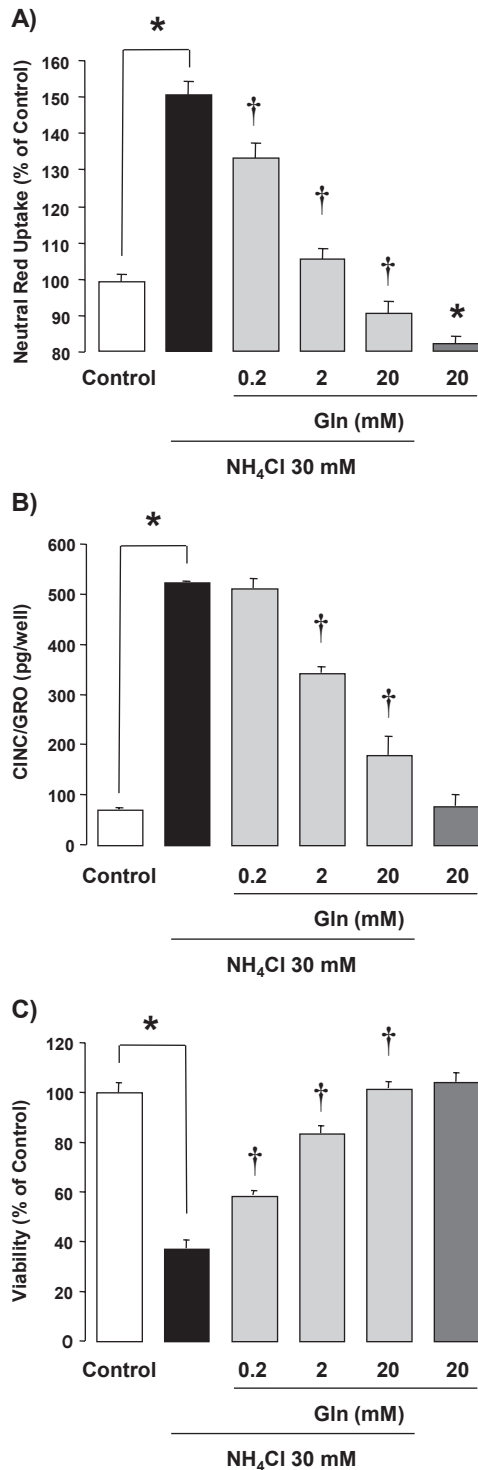


Fig. 5. Effects of glutamine and NH_4Cl on ammonia accumulation (A), CINC/GRO release (B), and cell viability (C) in RGM1 cells. The cells were incubated with or without the indicated concentration (mM) of glutamine (Gln) in the absence or presence of 30 mM NH_4Cl for 6 h (ammonia accumulation), 12 h (CINC/GRO release), and 24 h (cell viability) and then evaluated by each method. Data are presented as the mean \pm S.E.M. from 4 dishes. Significant difference at $P < 0.05$: *from Control, †from 30 mM NH_4Cl . (Adapted from Ref. 35 with permission.)

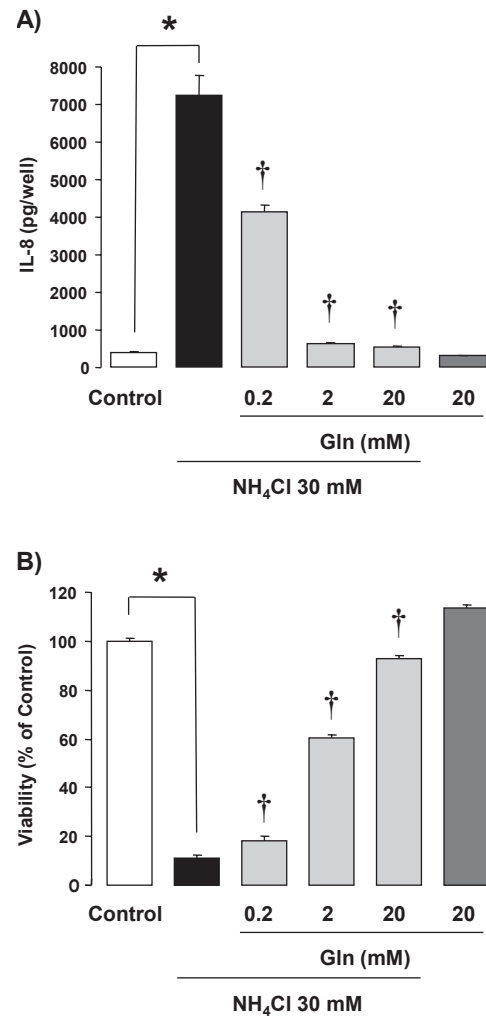


Fig. 6. Effects of glutamine and NH_4Cl on IL-8 release (A) and cell viability (B) in MKN74 cells. The cells were incubated with or without the indicated concentration (mM) of glutamine (Gln) in the absence or presence of 30 mM NH_4Cl for 24 h (IL-8 release) and 96 h (cell viability) and then evaluated by each method. Data are presented as the mean \pm S.E.M. from 4 dishes. Significant difference at $P < 0.05$: *from Control, †from 30 mM NH_4Cl .

1970s, glutamine is reportedly known to ameliorate gastric lesions induced by such pathogenic factors (25 – 29), and this amino acid is now used clinically as a gastroprotective drug in Japan. However, the underlying mechanism of the glutamine-induced gastric protection is still unclear. *H. pylori* infection has been recognized as another important pathogenic factor in the development of gastritis, gastric and duodenal ulcers, and gastric cancer (2, 4), but whether glutamine is effective for the treatment of *H. pylori*-related gastric diseases remains unknown.

It is well known that ammonia is one of the deleterious toxins produced by *H. pylori* (2, 4, 12 – 14, 17, 30 – 32).

In the patients infected with *H. pylori*, the concentration of ammonia (as NH_4^+) reaches approximately 10–50 mM (16). Previous studies unveiled that this range of ammonia concentration is toxic for gastric epithelial cells (12–14, 17, 30–32) and that the mechanisms involve the prolonged intracellular acidification and the decreased mitochondrial function by suppressing ATP production, resulting in cell death (12–14, 16, 17, 30–32). Thus, a reagent that inhibits the toxic effect of ammonia may be a promising drug for the treatment of gastric diseases caused by *H. pylori* infection. One of the present authors (EN) reported previously that glutamine potently protected RGM1 cells against ammonia-induced cell death (16). It is of interest to examine using gerbils the effect of long-term treatment of glutamine on *H. pylori*-induced pathological changes in the stomach.

In the gerbil stomach, *H. pylori* infection induces gastritis at 2 weeks, gastric ulcer at 6 months, and then progresses to induce gastric cancer at 15 months with highly stable prevalence (16, 18, 19, 33). In the present study, we confirmed in 3-month-infected gerbils that severe edema, surface congestion and some bleeding spots were observed in most areas of the gastric corpus, except for the area just close to the greater curvature. In 2-year-infected gerbils, the pathological changes became worse, that is, hyperplastic polyps and abnormal thickened mucosa with severe edema, bleeding, and ulcers were observed. Histological analyses revealed the occurrence of excess mucosal inflammation concomitant with parietal and chief cell atrophy. In addition, intestinal metaplasia was also seen as judged from goblet cells with sialomucin. These pathological changes were similar to those observed in humans (4, 34), indicating that the experimental system using gerbils is the best animal model for evaluation of *H. pylori*-induced gastric diseases (8, 18, 19, 33).

Surprisingly, glutamine as well as marzulene significantly ameliorated the *H. pylori*-induced pathological changes in the stomach, without affecting the number of viable *H. pylori*. *H. pylori* resides outside the body, that is, in the mucus layer of gastric lumen, that is far from the area where the bactericidal action by immune cells directly reaches (4). It is therefore assumed that the host protective response against *H. pylori*-derived toxin may be stimulated by glutamine, without direct action on *H. pylori*. To clarify the mechanisms by which glutamine or the glutamine-containing drug marzulene protects against the *H. pylori*-induced pathological changes in the stomach, we examined the effect of glutamine on the gastric epithelial responses to ammonia using RGM1 cells in vitro. As expected, the intracellular accumulation of ammonia, the release of chemokine, and the resulting cell death were all potently suppressed

by co-treatment with glutamine both in RGM1 cells (rat gastric epithelial cell line) and MKN74 cells (human gastric epithelial-like cell line). It was also noted in the in vitro experiments that glutamine should be co-incubated with ammonia for a longer time to obtain a potent protection. The same is true for the in vivo gerbil experiments. In our previous experiment, glutamine (solution) given three times daily showed less protection against *H. pylori*-induced gastritis compared with the present results using glutamine-containing diets, which remain in the stomach for much longer (unpublished data). It is thus assumed that glutamine should remain in the lumen of the stomach for a longer time to exert a potent protection. At present, the mechanism by which glutamine protects against *H. pylori*-induced gastric diseases remains unknown. However, it is assumed that the prophylactic effect of glutamine on ammonia-induced cell damage would mainly account for the protective action against *H. pylori*-induced gastric diseases, on the basis of the following reasons (16, 35): 1) many studies suggest the pathogenic importance of urease-derived ammonia in the formation of gastritis induced by *H. pylori*; 2) ammonia is accumulated in the cells, resulting in an increase in chemokine production and a decrease in cell viability; 3) gastric epithelial cells metabolize ammonia to urea via arginase, a process that is stimulated by glutamine and results in reduced ammonia cytotoxicity; 4) glutamine also inhibits the uptake and facilitates the extrusion of ammonia from cells, resulting in a decrease of chemokine production and cell death. Certainly, other mechanisms should also be involved in the protection by glutamine against *H. pylori*-induced gastric diseases, yet the elucidation of such mechanisms must await further study, especially using a gerbil infection in vivo model. Given the findings in the present study, we concluded that a high glutamine- or marzulene-containing diet protects the gastric mucosa against *H. pylori*-induced pathological changes. It may be assumed that facilitation by glutamine of the gastric epithelial function would be an interesting target for the treatment of *H. pylori*-induced gastric diseases.

References

- 1 IARC Monographs on the evaluation of carcinogenesis risks to humans. In: Schistosomes, liver flukes and *Helicobacter pylori*. Lyon, France: International Agency for Research on Cancer; 1994.
- 2 NIH Consensus Conference. *Helicobacter pylori* in peptic ulcer disease. NIH Consensus Development Panel on *Helicobacter pylori* in Peptic Ulcer Disease. JAMA. 1994;272:65–69.
- 3 Marshall BJ, Langton SR. Urea hydrolysis in patients with *Campylobacter pyloridis* infection. Lancet. 1986;1:965–966.
- 4 Fox JG, Wang TC. Inflammation, atrophy, and gastric cancer. J

- Clin Invest. 2007;117:60–69.
- 5 Fujikawa A, Shirasaka D, Yamamoto S, Ota H, Yahiro K, Fukada M, et al. Mice deficient in protein tyrosine phosphatase receptor type Z are resistant to gastric ulcer induction by VacA of *Helicobacter pylori*. Nat Genet. 2003;33:375–381.
 - 6 Higashi H, Tsutsumi R, Fujita A, Yamazaki S, Asaka M, Azuma T, Hatakeyama M. Biological activity of the *Helicobacter pylori* virulence factor CagA is determined by variation in the tyrosine phosphorylation sites. Proc Natl Acad Sci U S A. 2002;99:14428–14433.
 - 7 Higashi H, Tsutsumi R, Muto S, Sugiyama T, Azuma T, Asaka M, Hatakeyama M. SHP-2 tyrosine phosphatase as an intracellular target of *Helicobacter pylori* CagA protein. Science. 2002;295:683–686.
 - 8 Ogura K, Maeda S, Nakao M, Watanabe T, Tada M, Kyutoku T, et al. Virulence factors of *Helicobacter pylori* responsible for gastric diseases in Mongolian gerbil. J Exp Med. 2000;192:1601–1610.
 - 9 Fox JG. Review article: Helicobacter species and in vivo models of gastrointestinal cancer. Aliment Pharmacol Ther. 1998;12 Suppl 1:37–60.
 - 10 Fox JG, Li X, Cahill RJ, Andrutis K, Rustgi AK, Odze R, Wang TC. Hypertrophic gastropathy in *Helicobacter felis*-infected wild-type C57BL/6 mice and p53 hemizygous transgenic mice. Gastroenterology. 1996;110:155–166.
 - 11 Lee A. Helicobacter infections in laboratory animals: a model for gastric neoplasias? Ann Med. 1995;27:575–582.
 - 12 Matsui T, Matsukawa Y, Sakai T, Nakamura K, Aoike A, Kawai K. Ammonia inhibits proliferation and cell cycle progression at S-phase in human gastric cells. Dig Dis Sci. 1997;42:1394–1399.
 - 13 Suzuki H, Yanaka A, Muto H. Luminal ammonia retards restitution of guinea pig injured gastric mucosa in vitro. Am J Physiol Gastrointest Liver Physiol. 2000;279:G107–G117.
 - 14 Dekigai H, Murakami M, Kita T. Mechanism of *Helicobacter pylori*-associated gastric mucosal injury. Dig Dis Sci. 1995;40:1332–1339.
 - 15 Hagen SJ, Takahashi S, Jansons R. Role of vacuolation in the death of gastric epithelial cells. Am J Physiol. 1997;272:C48–C58.
 - 16 Nakamura E, Hagen SJ. Role of glutamine and arginase in protection against ammonia-induced cell death in gastric epithelial cells. Am J Physiol Gastrointest Liver Physiol. 2002;283:G1264–G1275.
 - 17 Suzuki H, Yanaka A, Shibahara T, Matsui H, Nakahara A, Tanaka N, et al. Ammonia-induced apoptosis is accelerated at higher pH in gastric surface mucous cells. Am J Physiol Gastrointest Liver Physiol. 2002;283:G986–G995.
 - 18 Watanabe T, Tada M, Nagai H, Sasaki S, Nakao M. *Helicobacter pylori* infection induces gastric cancer in mongolian gerbils. Gastroenterology. 1998;115:642–648.
 - 19 Takahashi S, Keto Y, Fujita H, Muramatsu H, Nishino T, Okabe S. Pathological changes in the formation of *Helicobacter pylori*-induced gastric lesions in Mongolian gerbils. Dig Dis Sci. 1998;43:754–765.
 - 20 Kobayashi I, Kawano S, Tsuji S, Matsui H, Nakama A, Sawaoka H, et al. RGM1, a cell line derived from normal gastric mucosa of rat. In Vitro Cell Dev Biol Anim. 1996;32:259–261.
 - 21 Cover TL, Dooley CP, Blaser MJ. Characterization of and human serologic response to proteins in *Helicobacter pylori* broth culture supernatants with vacuolizing cytotoxin activity. Infect Immun. 1990;58:603–610.
 - 22 Cover TL, Vaughn SG, Cao P, Blaser MJ. Potentiation of *Helicobacter pylori* vacuolating toxin activity by nicotine and other weak bases. J Infect Dis. 1992;166:1073–1078.
 - 23 Keisari Y. A colorimetric microtiter assay for the quantitation of cytokine activity on adherent cells in tissue culture. J Immunol Methods. 1992;146:155–161.
 - 24 Okabe S, Takeuchi K, Takata Y, Naganuma T, Takagi K. Effects of L-glutamine on various gastric lesions in rats and guinea pigs. Digestion. 1976;14:325–331.
 - 25 Okabe S, Takeuchi K, Honda K, Takagi K. Effects of acetylsalicylic acid (ASA), ASA plus L-glutamine and L-glutamine on healing of chronic gastric ulcer in the rat. Digestion. 1976;14:85–88.
 - 26 Okabe S, Honda K, Takeuchi K, Takagi K. Inhibitory effect of L-glutamine on gastric irritation and back diffusion of gastric acid in response to aspirin in the rat. Am J Dig Dis. 1975;20:626–631.
 - 27 Okabe S, Hung CR, Takeuchi K, Takagi K. Effects of L-glutamine of acetylsalicylic acid or taurocholic acid-induced gastric lesions and secretory changes in pylorus-ligated rats under normal or stress conditions. Jpn J Pharmacol. 1976;26:455–460.
 - 28 Okabe S, Otsu K, Takeuchi K, Takagi K. Effect of L-glutamine on indomethacin-induced gastric lesions in the rat. Jpn J Pharmacol. 1974;24:169–171.
 - 29 Okabe S, Takeuchi K, Nakamura K, Takagi K. Inhibitory effect of L-glutamine on the aspirin-induced gastric lesions in the rat. J Pharm Pharmacol. 1974;26:605–611.
 - 30 Kawano S, Tsujii M, Fusamoto H, Sato N, Kamada T. Chronic effect of intragastric ammonia on gastric mucosal structures in rats. Dig Dis Sci. 1991;36:33–38.
 - 31 Tsujii M, Kawano S, Tsuji S, Fusamoto H, Kamada T, Sato N. Mechanism of gastric mucosal damage induced by ammonia. Gastroenterology. 1992;102:1881–1888.
 - 32 Tsujii M, Kawano S, Tsuji S, Ito T, Nagano K, Sasaki Y, et al. Cell kinetics of mucosal atrophy in rat stomach induced by long-term administration of ammonia. Gastroenterology. 1993;104:796–801.
 - 33 Keto Y, Ebata M, Okabe S. Gastric mucosal changes induced by long term infection with *Helicobacter pylori* in Mongolian gerbils: effects of bacteria eradication. J Physiol Paris. 2001;95:429–436.
 - 34 Merchant JL. Inflammation, atrophy, gastric cancer: connecting the molecular dots. Gastroenterology. 2005;129:1079–1082.
 - 35 Nakamura E, Hayashi S, Endo T, Amagase K, Okabe S, Takeuchi K. [Prophylactic effect of glutamine and marzulene against *Helicobacter pylori*-related gastric diseases in Mongolian Gerbils.] Jpn Pharmacol Ther. 2007;35:479–488. (text in Japanese with English abstract)